

# Through the Eye of the Suprasternal Notch Searching For TB



## Notch Searching For TB

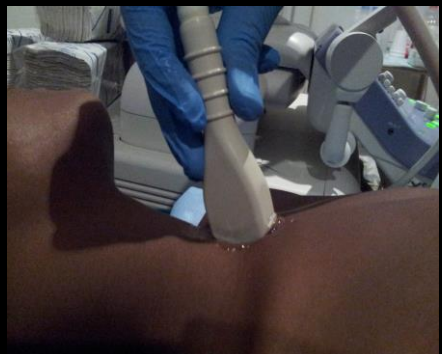
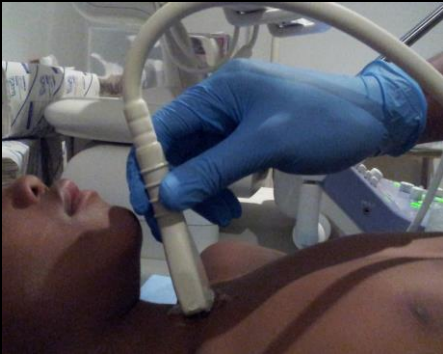
Tsepo Moseme and Savvas Andronikou  
Department of Radiology, Faculty of Health Sciences, University of the Witwatersrand

**Try this technique for mediastinal lymphadenopathy in children with suspected pulmonary TB.**  
We developed and tested this simplified technique of mediastinal ultrasound in a pilot of 30 children (0 to 13 years) with proven or suspected TB through the suprasternal notch.

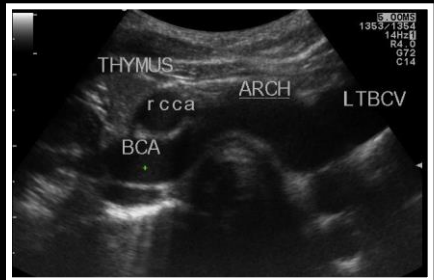
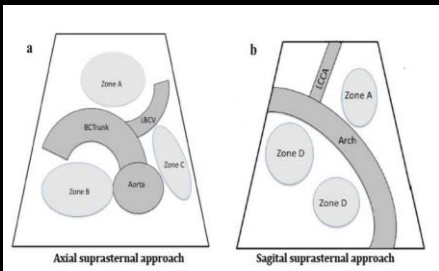
A coronal oblique (axial) view is created by placing the probe transversely at the suprasternal notch and angling inferiorly to look into the chest

Rotating the probe through 45 degrees clockwise and again angling inferior into the chest creates a sagittal oblique view along the aortic arch.

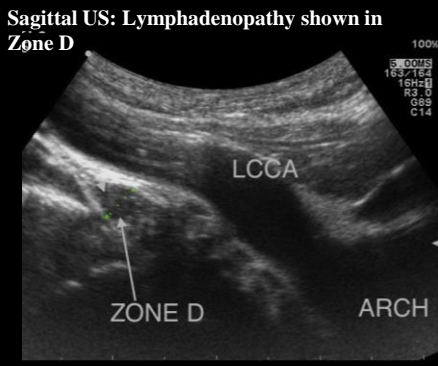
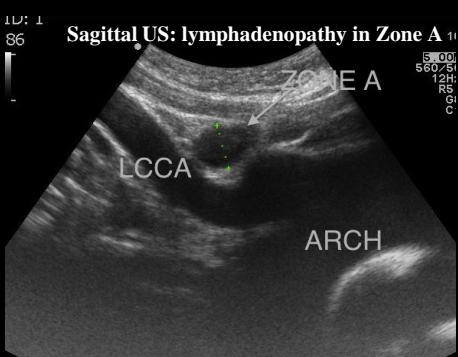


Schematic: anatomy and zonal distribution of possible lymphadenopathy

US normal axial anatomy:



**Pathology:** Lymphadenopathy is echogenic as opposed to vascular structures which are anechoic. We demonstrated the vascular anatomy in all 30 children and lymphadenopathy in 12.



**Conclusion:** Mediastinal ultrasound for detecting lymphadenopathy is a feasible, reliable, non-invasive method for children with suspected pulmonary tuberculosis. In the rural district health care setting US is often the only available imaging and it is mobile, making it possible to examine patients at the point of care.