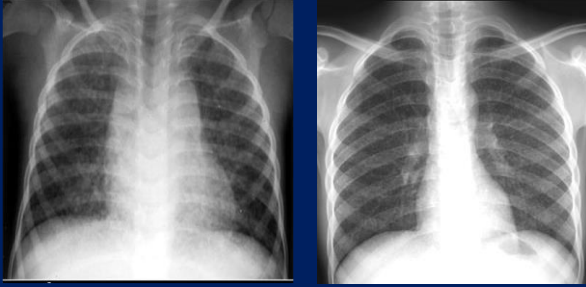


# Radiological progression of nodular infiltrates in HIV-infected South African children



## Introduction:

A nodular pattern on chest X-ray (CXR) is common in HIV-infected children and has a wide differential diagnosis. There is limited knowledge of the natural history and clinical associations of pulmonary nodules in HIV-infected children in low- and middle- income countries.

## Aim:

To describe longitudinal radiological changes in pulmonary nodules in HIV-infected South African children, with clinical or immunological associations.

## Methods:

We conducted a 5-year prospective longitudinal study of HIV-infected children on a Cape Town INH prophylaxis trial. Clinical and immunological parameters were measured. CXR's were done on enrolment, 6-monthly and during episodes of acute infection.

## Results:

258 children were followed for a median of 24 months (IQR: 18-42).

At enrolment, 71 (27.5%; male=40), median age 39 months (IQR: 24.5-56) and median CD4+ 18% (IQR:14-26%) demonstrated a nodular pattern; 16/71 (22.5%) were on anti-retroviral therapy (ART) and 12/71 (16.9%) had pulmonary tuberculosis (PTB).

25 (35%), median CD4+ 31% (IQR: 20-37%), showed persistent pulmonary nodules at 24 months (Table 1).

In those showing resolution (n=46,65%), the median CD4+(IQR) at the time of clearing was 24% (IQR:18-29%). Resolution in PTB patients was similar to the whole group; patients on ART tended to earlier resolution (Figures 1, 2).

## Conclusion:

The majority of patients with pulmonary nodularity show radiographic clearing associated with improved CD4+ percentages. Nodules persisting beyond 18 months may not be associated with immune suppression.

Follow-up (months)	Whole group		ART	TB
	median CD4+% (IQR)	n=71(%)	n=16(%)	n=12(%)
6m	17(12-25)	61(86)	10(62)	10(83)
12m	23(17-30)	47(66)	8(50)	8(67)
18m	25(18-31)	34(47)	6(38)	6(50)
24 m	31(20-37)	25(35)	4(25)	5(42)

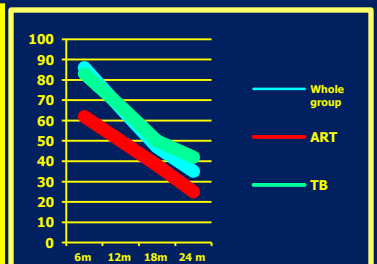
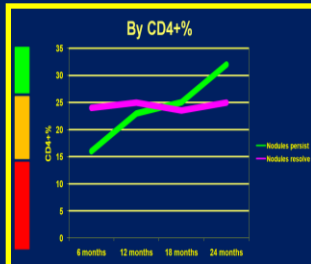


Table 1. Persistence of pulmonary nodules

Figure 1. Persistence of nodules by CD4+%

Figure 2. Persistence of nodules by ART, PTB

Richard D. Pitcher MB.ChB FCRad(D)SA<sup>1</sup>, Carl Lombard M.Sc.Ph.D<sup>2</sup>, Mark F. Cotton MB.ChB MMed FCPaed(SA) Ph.D<sup>3</sup>, Stephen J. Beningfield MB.ChB FCRad(D)SA<sup>4</sup>, Heather J. Zar MB.BCh FCPaed (SA) Ph.D<sup>5</sup>.

1.Division of Radiodiagnosis, Tygerberg Hospital, Stellenbosch University, Cape Town, South Africa.

2.Biostatistics Unit, Medical Research Council, South Africa.

3.Department of Paediatrics and Child Health, Tygerberg Children's Hospital and Stellenbosch University.

4.Division of Radiology, New Groote Schuur Hospital and University of Cape Town

5.Department of Paediatrics and Child Health, Red Cross War Memorial Children's Hospital, University of Cape Town, South Africa